CASE REPORT

# Management of a Symblepharon Case by Auto Conjunctival Graft: A Clinical Case Report

**Raghunandan Khandelwal*, Archana Garg**, Rakesh Porwal*****

## ABSTRACT

**Background:** A twelve years old male child presented in our OPD with symblepharon in the inferior cul de sac of the right eye with H/O lime chemical injury 23 days back. The patient was complaining about eye mass, redness, watering, foreign body sensation, and cosmetic consideration in the right eye. His visual acuity was 6/18 in the right eye. IOP in both eyes was 14.6 mm of Hg at the time of admission. The cornea was partially opaque near the symblepharon site and extra-ocular movements were partially restricted due to adhesion.

**Management:** symblepharonectomy has been performed in the inferior cul-de-sac of the right eye. The auto conjunctival graft was taken from the superior conjunctiva of the same eye and sutured to the symblepharonectomy site of the right eye. A conformer was placed to the right eye to prevent recurrent symblepharon.

**Discussion:** Next day evaluation showed an inferior cul-de-sac of the right eye was formed, and the conjunctiva was viable and ready to get an ocular prosthesis. Conjunctival graft and conformer placing can prevent recurrent symblepharon after symblepharonectomy. It may provide a cheap and simple way to form a barrier that prevents reattachment of the eyeball and eyelids.

**Keywords:** symblepharonectomy, auto conjunctival graft, conformer.

## INTRODUCTION

Symblepharon is a pathological condition where the bulbar and palpebral conjunctiva form an abnormal adhesion to one another[1]. Most cases of symblepharon are acquired. It may be caused by autoimmune diseases, mechanical, thermal, or chemical injury, and as a complication of conjunctival surgery[2]. Treatment of symblepharon by chemical injury is challenging as it may be accompanied by tear film instability, tear reduction, and cicatricial entropion. In the later stage, there may be the development of irregular corneal surface, inflammation, conjunctivalization, corneal vascularization, and poor epithelial integrity[3] which may lead to the dysfunction of the ocular surface and may affect the treatment and prognosis of symblepharon. Surgical correction with lubricant application is the mainstay of treatment. Symblepharectomy invariably creates a defect in the conjunctiva. If left uncovered, might result in re-adhesion of the exposed surfaces. To cover the defects conjunctival[4], the amniotic membrane, oral mucosa, and nasal mucosa are alternative tissues.

## CASE REPORT

A 12-year-old male child presented to our Out Patient Department on 5th June 2022 with the chief complaint of mass in the right eye for the last 8-10 days as seen in Figure 1. The pain was dull aching in nature associated with redness, watering, and foreign body sensation. There is a history of lime chemical injury. There is no history of any ocular disease or surgery. There is no history of other systemic diseases. ·

**Examination of the right eye**

- Visual acuity: 6/18, N/6
- Pupil: Normal
- Colour vision: Normal
- Eyelid: Adhesion of the lower lid at the center.
- Eyelashes: Normal
- Palpebral aperture: Normal

Conjunctiva: Congested with the adhesion of bulbar and palpebral conjunctiva at the inferior fornix.

- Sclera: Normal
- Iris: Normal

*Resident Doctor, **Associate Professor, ***Senior Professor
Department of Ophthalmology, JLN Medical College, Ajmer.
**Corresponding Author**:
Dr. Raghunandan Khandelwal
Final Year Resident
Department of Ophthalmology, JLN Medical College, Ajmer
Mob. 9252255211
dr_raghusms@rediffmail.com

- Anterior chamber: Normal
- Lens: Clear

Extra ocular movements were partially restricted due to adhesion.

- Nasolacrimal duct : patent
- IOP: 14.6 mm Hg
- Fundus: WNL

· **Investigations**

- Routine CBC & Blood examination: WNL
- Liver function tests: WNL
- Renal function test: WNL
- HBsAg test: negative
- HIV test: negative

Based upon the clinical and diagnostic workup, a provisional diagnosis of partial anterior symblepharon due to chemical injury was made.

## MANAGEMENT

The patient was initially managed conservatively with antibiotic eye drops and lubricants and planned for symblepharonectomy with auto conjunctival graft placement. Lid traction sutures were applied for adequate exposure. The conjunctival incision was made along the ends of the symblepharon and undermined from Tenon's capsule to allow the conjunctiva to retract to its normal anatomical position. The sub conjunctival fibrous tissue was excised to the maximum extent possible, and all adhesion was released. Ocular surface reconstruction was done by auto conjunctival graft to cover the bare sclera, reform the fornix, and cover the denuded palpebral conjunctiva up to the edge of the recessed symblepharon conjunctiva.

## DISCUSSION

The intense inflammatory process due to chemical trauma will cause a progressive cicatricial process, which will limit the movement of the eyeball due to the formation of symblepharon. Treatment with symblepharonectomy alone is will result in repeated symblepharon because there is still contact between the rough surface of the eyeball and the eyelid, so to prevent it sealer is needed. Use of auto conjunctival graft to cover the bare sclera and conformer after symblepharonectomy is a cheap and simple way to form a barrier that prevents reattachment of the eyeball and eyelids[5]. Visual improvementwas noted on postoperative day 1 and subsequent follow-up after 2 weeks with good cosmetic consideration.

**Fig. 1 Preoperative**

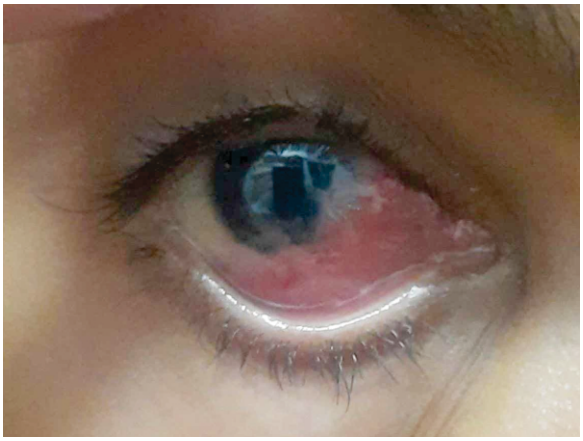

**Fig. 2 Post operative**

## REFERENCES


1. Symblepharon, Available from: *https://eyewiki.aao.org/Symblepharon#Disease*
2. Chen L, Zhang S, Yan C. Evaluation of chronic ocular sequelae in patients with symblepharoncaused by ocular burns. *Int J Ophthalmol*, Jul.18, 2020 Vol.13, No.7
3. Tseng SC. Concept and application of limbal stem cells. *Eye (Lond).* 1989;3(Pt 2):141-157.
4. Kaufman HE, Thomas EL. Prevention and treatment of symblepharon. *Am J Ophthalmol.* 1979;88(3 Pt 1):419-423.
5. Sutjipto, Doemilah R. Auto Conjunctival Graft and Conformer Placing after Symblepharectomy. *Jurnal Oftalmologi Indonesia*. June 2009 Vol. 7, No.1